

# Shifting focus: implications of periwound bacterial load on wound hygiene

Rosemary Hill BSN CWOCN CETN (C), Joshua Douglas MD, FRCPC, ABIM

Infectious Disease and Critical Care Internal Medicine, Vancouver Coastal Health

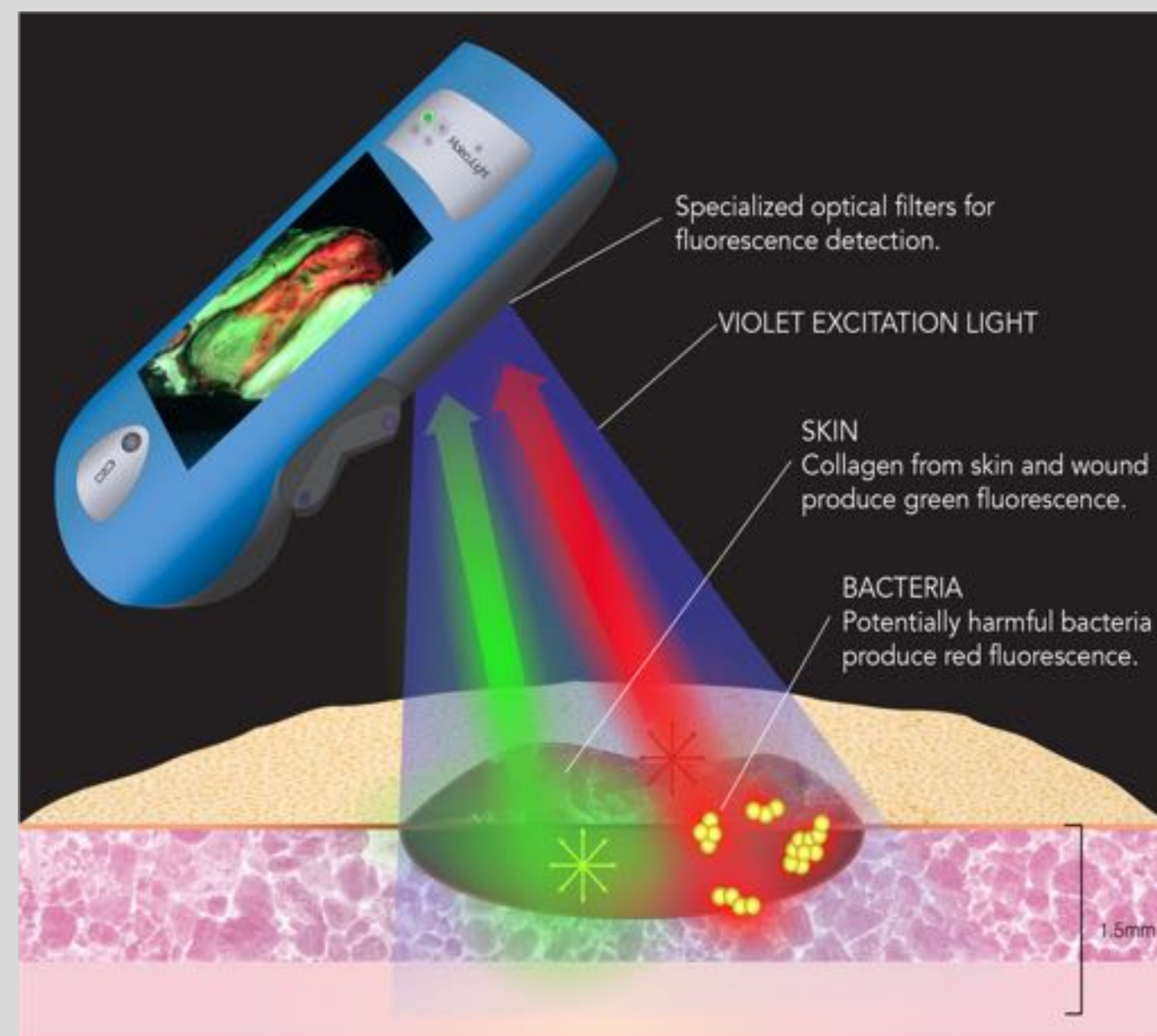
## INTRODUCTION

- Wound cleansing is the most ubiquitous method to maintain optimal wound hygiene as it is available at all clinical settings and skill levels.
- The periwound is often a neglected area, but serves as a source for microbial recontamination if not adequately cleansed.
- Fluorescence imaging has been used to visualize fluorescing bacteria in real-time at the bedside using a non-contact device<sup>2-4</sup>.
- This study reports the use of bacterial fluorescence imaging to assess bioburden in the wound and periwound area to optimize wound hygiene using a new cleansing agent, using lower concentration sodium hypochlorite (NaOCl), compared to standard practice.

## METHODS

### Bacterial Fluorescence Imaging

- When excited by 405 nm violet light, tissues fluoresce **green** while bacteria fluoresce **red** (e.g. *Staphylococcus aureus*) or **cyan** (e.g. *Pseudomonas aeruginosa*).
- This enables real-time, point-of-care detection and localization of bioburden ( $\geq 10^4$  CFU/g) within and around wounds<sup>2-4</sup>.

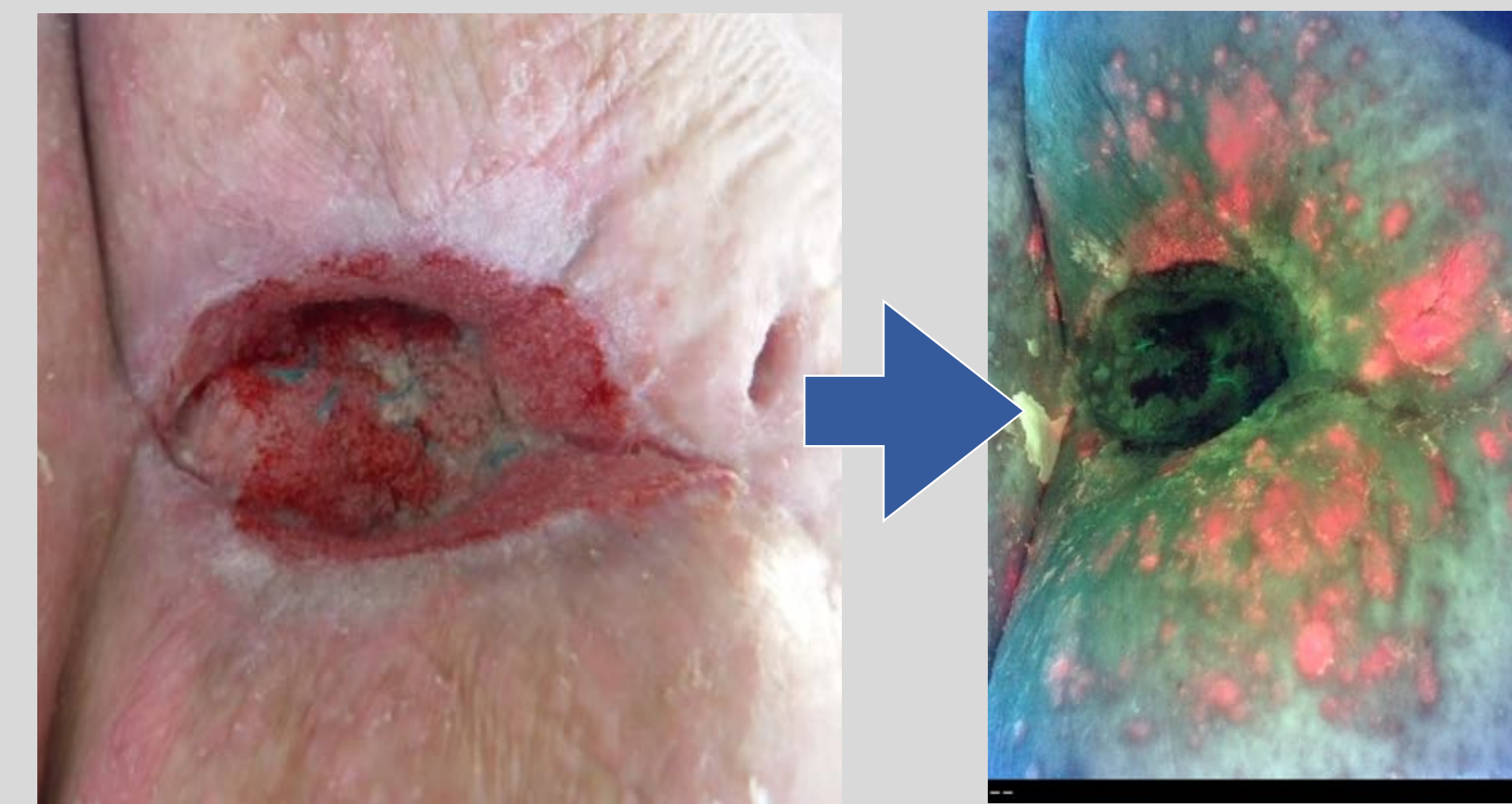

- Bacterial fluorescence imaging was incorporated into assessment of 10 wounds of mixed etiology (e.g. DFU, VLU, SSI, PU).
- Fluorescence imaging was performed at baseline, after cleaning with saline and after cleaning with low concentration sodium hypochlorite.
- Fluorescence images were used to assess presence of bioburden after each cleansing step and determine the region to target further cleansing or debridement if cleansing did not eliminate the bioburden.

## RESULTS

Visualization of bacterial load can be incorporated into routine wound care to optimize wound hygiene by guiding targeted cleansing

Standard practice cleansing with saline was performed on 10 wounds in this study.



ST-image

FL-image

### Case 1:

- 72 year old male treated with NPWT after midline surgery complication
- Distinct odour observed at the time of assessment
- Swab obtained from the wound bed prior to fluorescence imaging were negative for bacterial growth
- Red fluorescence indicates presence of bacteria


Based on fluorescence images after initial saline cleanse, in which **bacterial (red) fluorescence was present in 100% of wounds**, clinician chose to more aggressively cleanse all 10 wounds using low concentration sodium hypochlorite, specifically targeting regions of bioburden. 3 cases are demonstrated.

Baseline - ST-image

Baseline - FL-image

After saline

After NaOCl

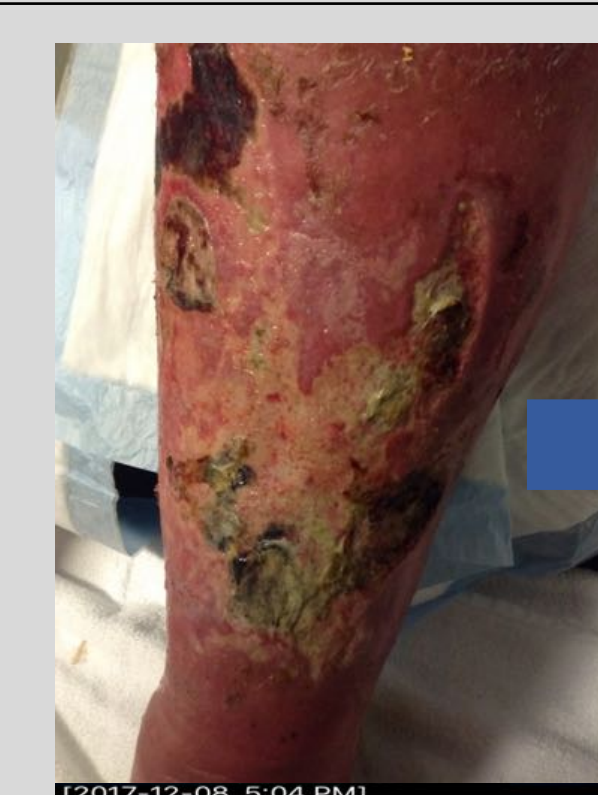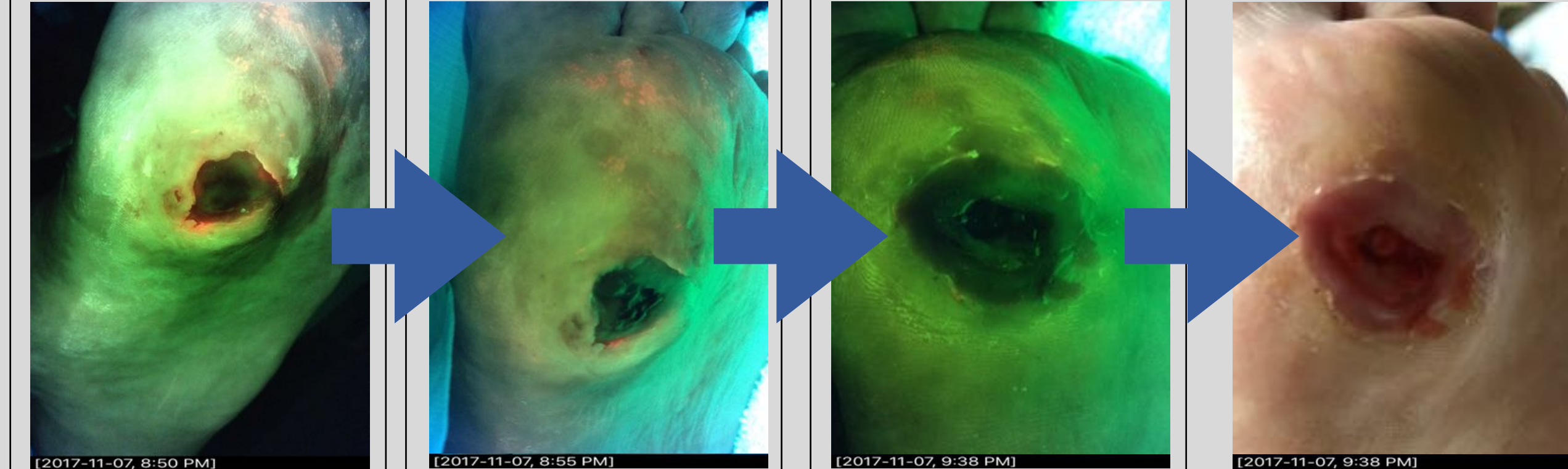


### Case 2: Skin Tear

- Saline cleanse was moderately effective in removing red fluorescent bacteria
- NaOCl cleanse successfully removed red fluorescing bacteria

### Case 3: DFU

- Red fluorescing bacteria present at the wound bed and peri-wound site.
- Saline cleanse did not eradicate fluorescent bacteria
- NaOCl cleanse successfully removed all red fluorescence



### Case 4: VLU with necrosis

- Cleansing with saline did not remove cyan or red fluorescing bacteria
- NaOCl was very effective on cyan fluorescing bacteria
- Red fluorescence remained after NaOCl cleanse and the patient required debridement

## RESULTS

# of Wounds Cleansed		
Initial periwound fluorescence	Periwound fluorescence after saline cleanse	Periwound fluorescence after low concentration NaOCl
10/10	10/10	3/10

Note: Off-site bacteria was also observed in all 10 wounds

## CONCLUSIONS

- Bacterial (red and/or cyan) fluorescence was present in the periwound area in 100% of wounds. The fluorescence persisted after initial, standard of care cleansing with saline.
- This is concerning given that red fluorescence equates to a bacterial load of  $10^4$  CFU/g or higher (i.e. moderate/heavy bacterial loads)<sup>4</sup>.
- 30% of wounds required debridement after cleansing with low concentration sodium hypochlorite solution (NaOCl)
- Thus, results of this study demonstrate that bacteria is located outside of the wound bed, and poses a cross-contamination risk. Current best cleansing practices using saline:
  - do not maximize removal of bioburden, and
  - leave behind an unacceptably high bacterial load ( $\geq 10^4$  CFU/g) that is considered detrimental to wound healing<sup>5</sup>
- Incorporation of bacterial fluorescence imaging into routine wound care resulted in more aggressive cleansing. This specifically targeted regions of bioburden, and indicated to the clinician if additional therapy (e.g. debridement) was required to fully eliminate the bioburden.
- Results highlight the potential of bacterial fluorescence imaging to dramatically improve current cleansing practices by enabling point-of-care, bioburden based decision making on when cleansing is sufficient, and when additional techniques are required to remove bioburden.

## REFERENCES

- International Best Practice: Wound Management in DFUs. Wounds International, 2013.
- DaCosta RS et al. Point-of-Care Auto-fluorescence Imaging for Real-Time Sampling and Treatment Guidance of Bioburden in Chronic Wounds: First-in-Human Results. PLoS ONE, 2015.
- Ottolino-Perry et al. Improved detection of wound bacteria using autofluorescence image-guided wound sampling in diabetic foot ulcers. International Wound Journal, 2017
- Rennie MY et al. Point-of-care fluorescence imaging positively predicts the presence of pathogenic bacteria in wounds at loads  $\geq 10^4$  CFU/g: a clinical study. J Wound Care (submitted).
- Edwards R and Harding KG. Bacteria and wound healing. Curr Opin Infect Dis. 2004.

**Acknowledgement:** Financial support to attend this meeting was provided by MolecuLight, Inc. The bacterial fluorescence imaging device used in this study is manufactured and sold by MolecuLight, Inc.