

# The use of the MolecuLight bacterial camera in the management of bacterial load in burn patients



Lt Col SLA Jeffery, RAMC<sup>1,2</sup> and Emily Blumenthal<sup>1</sup>

<sup>1</sup>Queen Elizabeth Hospital (Birmingham, United Kingdom), and <sup>2</sup>The Royal Centre for Defence Medicine (United Kingdom)



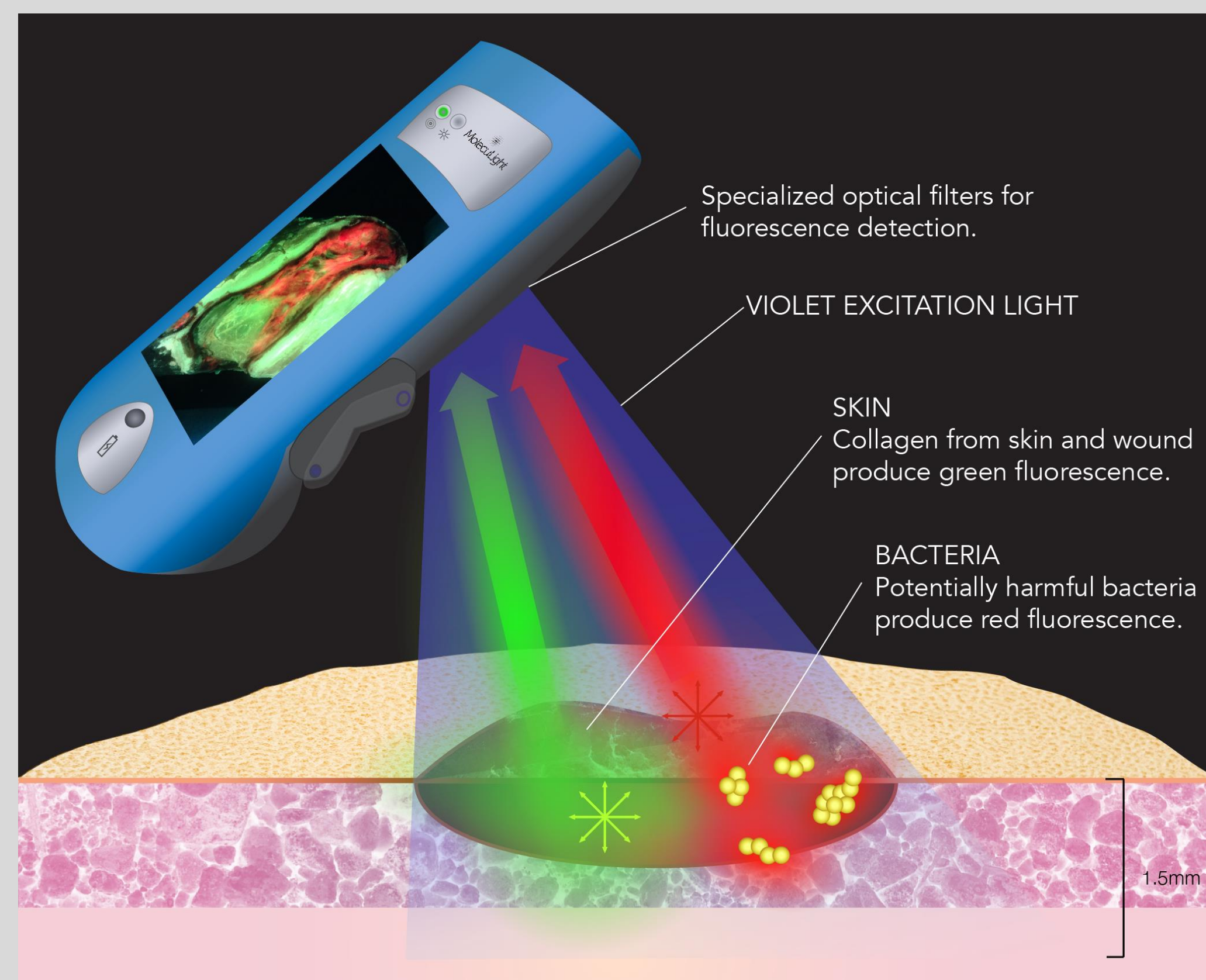
## INTRODUCTION

- Damage to skin and soft tissue via traumatic burn wounds allows for opportunistic pathogens to complicate and impede the normal course of healing and repair<sup>1</sup>.
- The diagnosis of microbial infection in a wound, based on common clinical signs and symptoms is difficult, as there is no gold standard to predict bacterial activity in tissue and bacteria are invisible to the unaided eye.
- Fluorescence imaging has recently been used to visualize clinically significant levels of pathogenic bacteria in real-time at the bedside using a non-contact hand held device<sup>2,3</sup>.
- We aimed to assess the effectiveness of this device in the detection and management of bacterial load in burn patients.

## METHODS

### Bacterial Fluorescence Imaging

- When excited by 405 nm violet light, tissues fluoresce green while bacteria fluoresce red (porphyrin-producers) or cyan (pyoverdine-producing *Pseudomonas aeruginosa*).
- This enables real-time, point-of-care detection and localization of bioburden ( $\geq 10^4$  CFU/g) within and around wounds<sup>2-5</sup>.



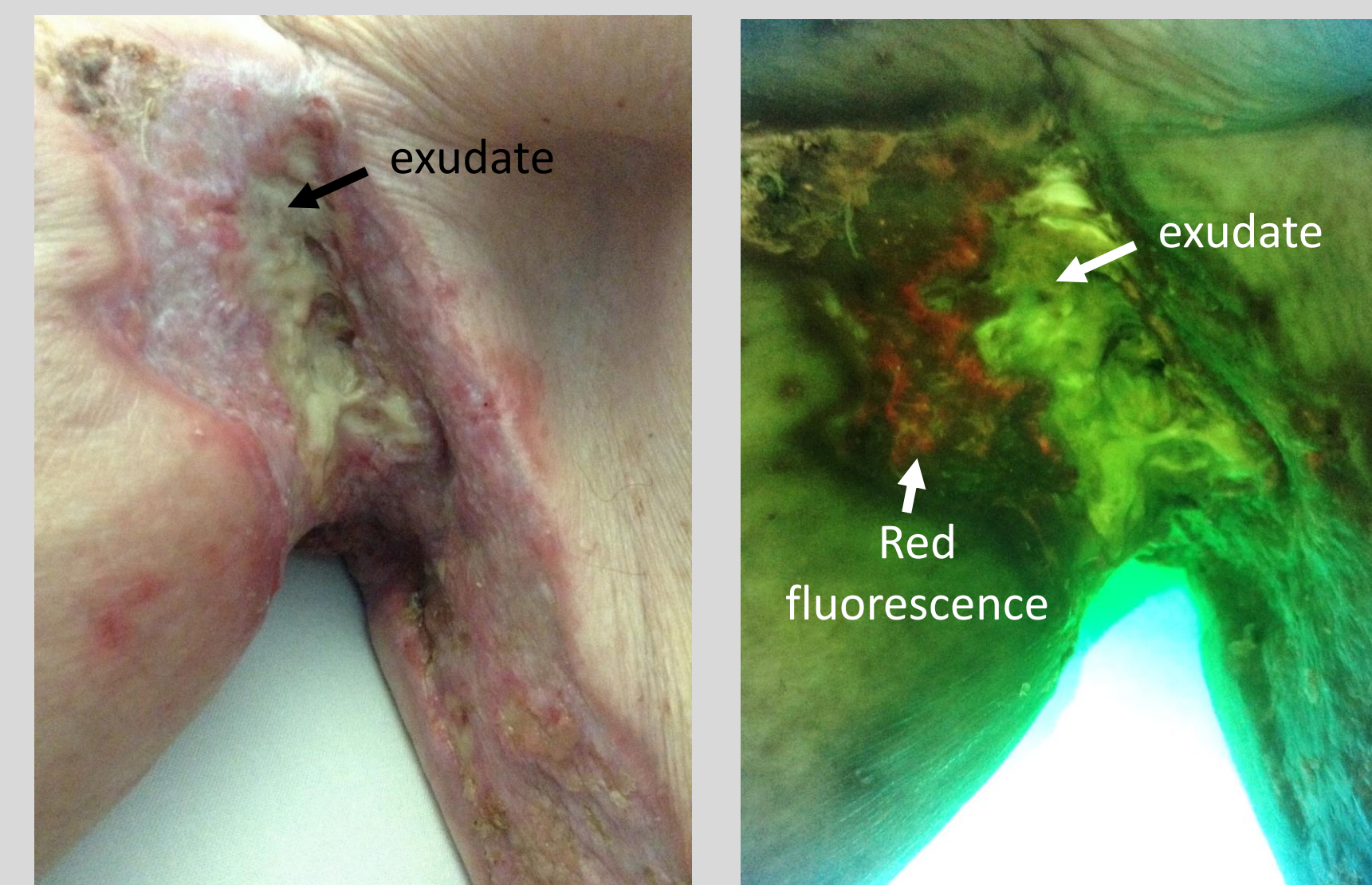
### Series of Thirty Burn Patients

- Thirty burn care patients were imaged for bacterial fluorescence at various points during their treatment (usually during dressing changes) and swabs were taken to confirm the presence or absence of bacteria.
- Wounds that were positive for red or cyan fluorescence signal were considered to be contaminated with bacteria.

## RESULTS

- 12 of 30 patients did not exhibit bacterial fluorescence (red or cyan) on images captured at the point of care. Swab results confirmed the absence of bacteria in all 12 cases (100%).
- The remaining 18 patients exhibited red or cyan on fluorescence images, suggesting the presence of bacteria. In each case, these findings were supported by clinical signs and symptoms and by microbiology results with growth of *Pseudomonas aeruginosa* (cyan fluorescing bacteria), *Staphylococcus aureus* (red fluorescing bacteria), and various other pathogens.
- Images revealing the absence or presence and specific location of bacterial burden guided patient management in various ways. Four cases are discussed.

### Fluorescence imaging targets swabbing to region of bioburden

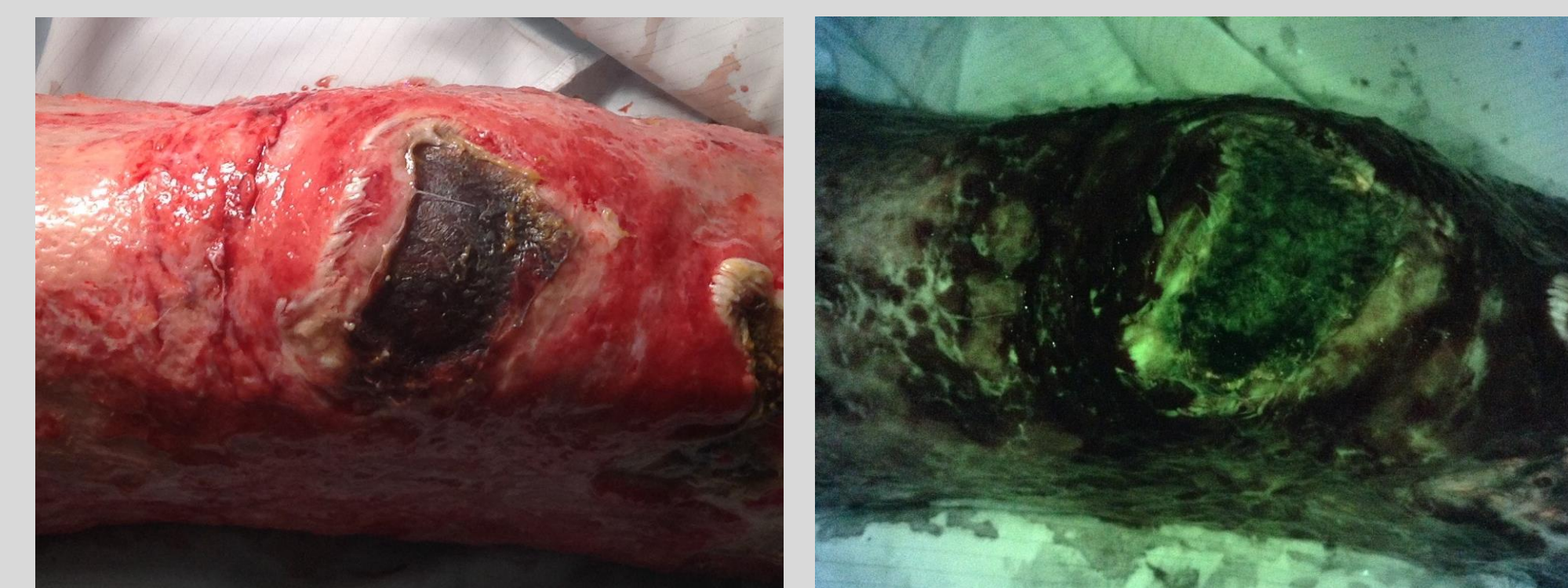

Standard Imaging Mode      Fluorescence Imaging Mode

85-year-old male suffered deep dermal and full thickness contact burns to the right axilla, forearm, and scapula. Swabs taken from exudate in days prior to imaging were negative. Fluorescence images revealed red fluorescence on outlying tissue, not on exudate, guiding targeted swabbing of the red region.

Swabs confirmed growth of *Staphylococcus aureus* and *E. coli*.

### Fluorescence imaging allows for confidence when skin grafting

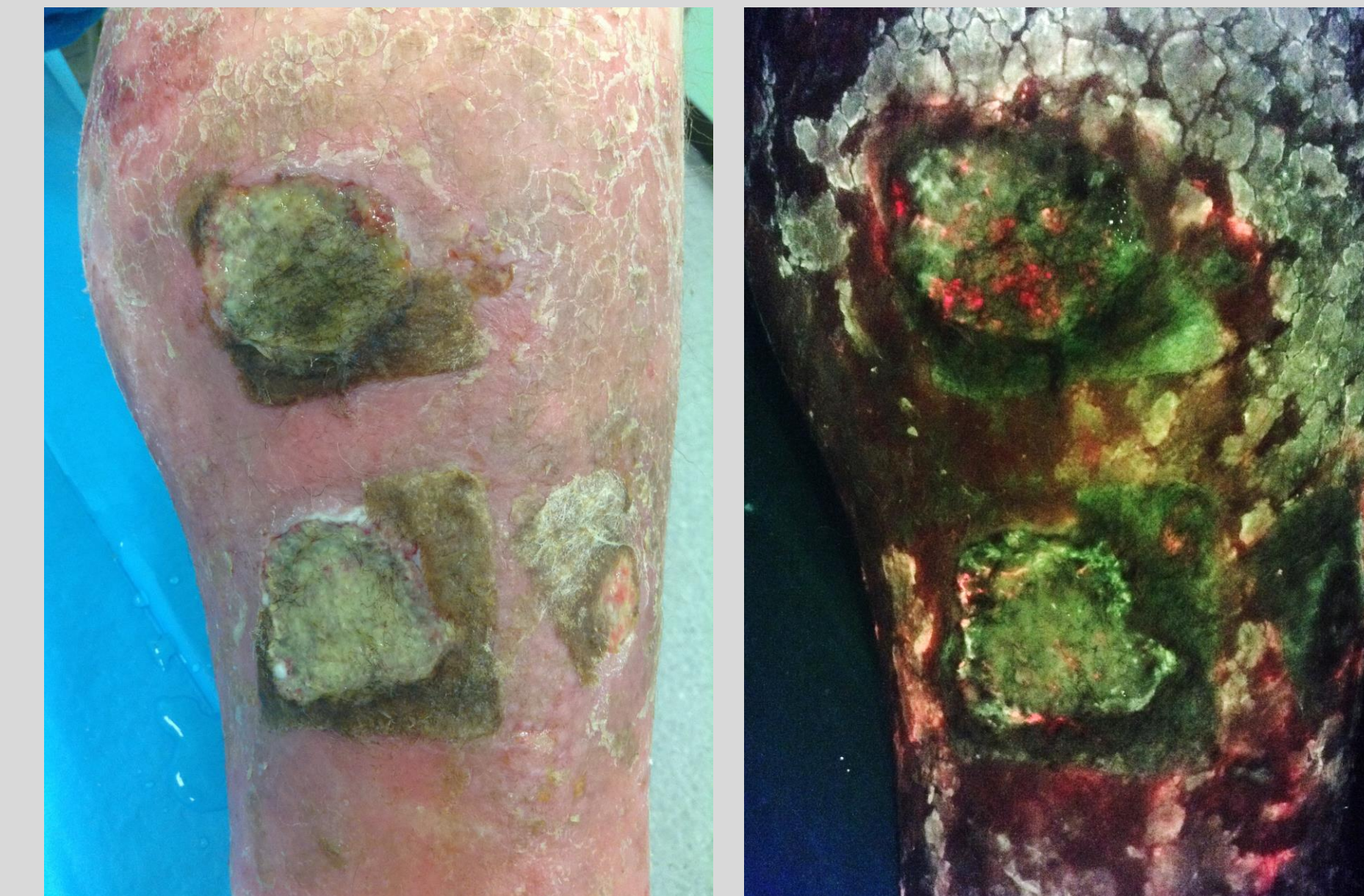


Standard Imaging Mode      Fluorescence Imaging Mode

58-year-old man suffered deep burns down to the bone on right leg. Fluorescence images were acquired to determine whether region was a candidate for skin grafting (contraindicated when bioburden present). No fluorescence signals that would suggest bacterial presence were found.

Swabs confirmed no growth of bacteria.

### Bacterial Fluorescence Guides Antimicrobial Decision Making and Monitors Treatment Effectiveness

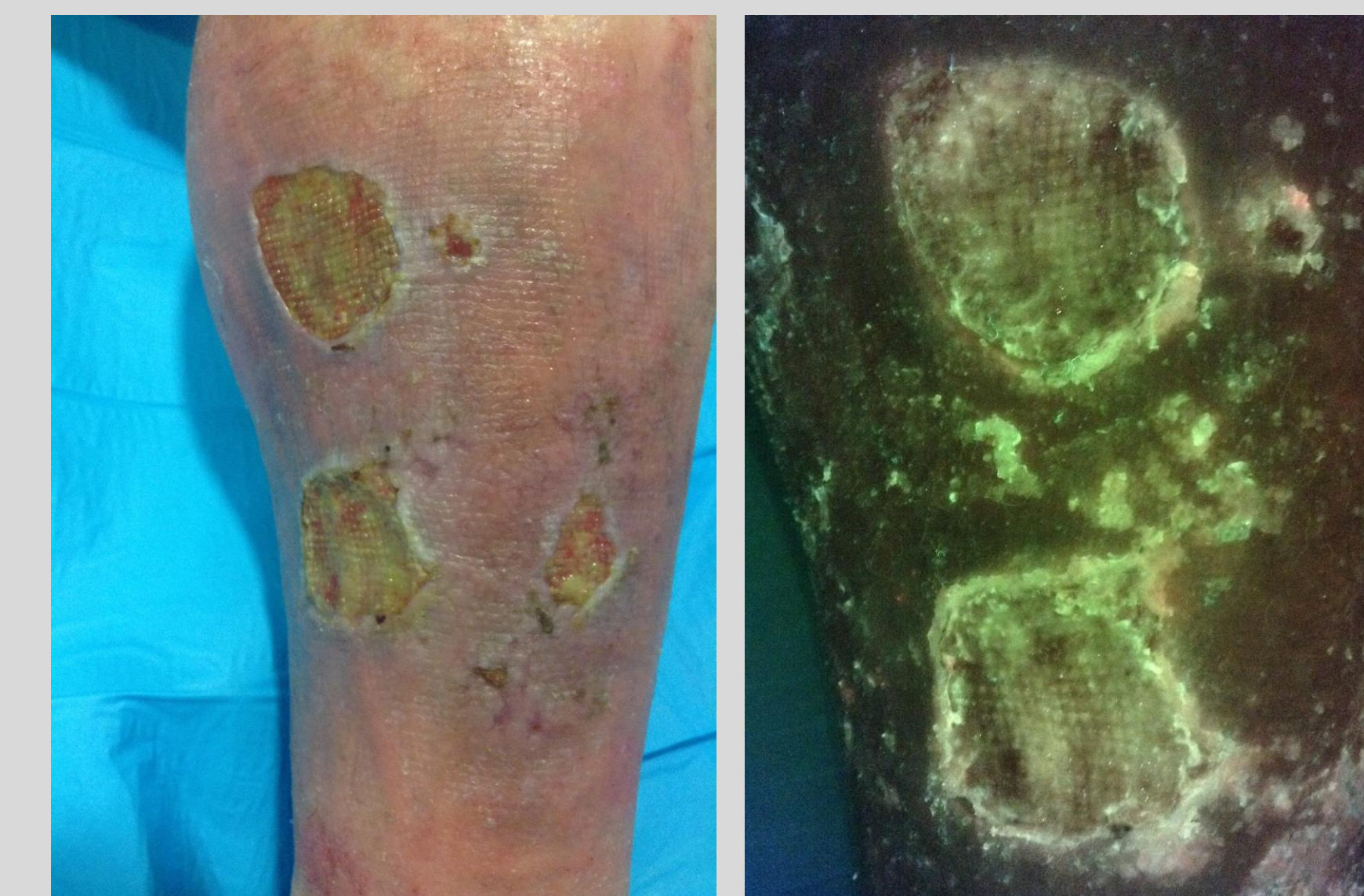

Standard Imaging Mode      Fluorescence Imaging Mode

Male patient spilled battery acid onto left calf, left burns untreated for several weeks. Came to burn unit when leg was swollen, red and foul smelling. Ultrasound revealed deep vein thrombosis. Wound initially treated with antimicrobial scrub and dressing. However, fluorescence images revealing widespread bacterial (red) fluorescence within and around the wounds guided the prescription of a course of antibiotics.

Swabs later confirmed heavy growth of *Staphylococcus aureus*.

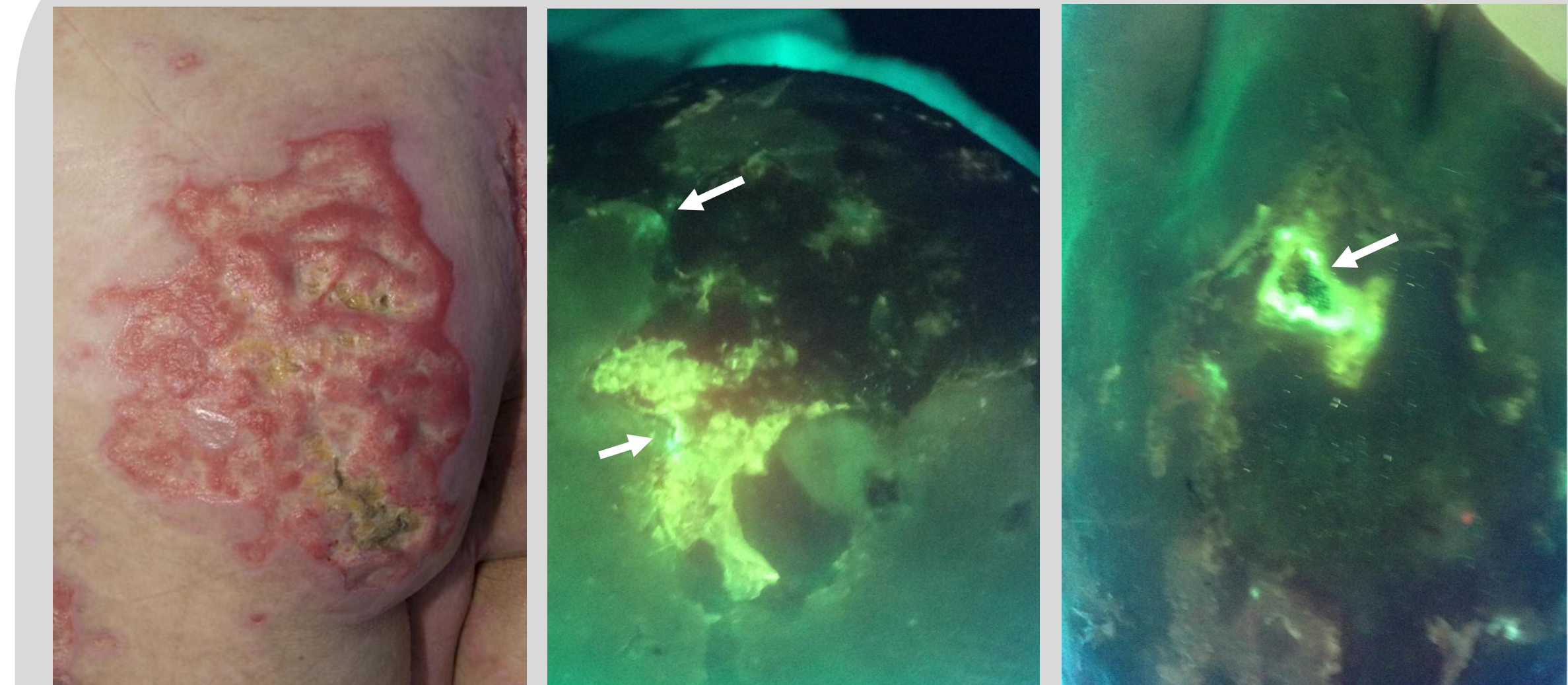
### Monitoring Antibiotic Treatment Effectiveness



Standard Imaging Mode      Fluorescence Imaging Mode

Subsequent images acquired after three days of prescribed antibiotic demonstrated a dramatic decrease in bacterial (red) fluorescence. The wounds were therefore deemed to be significantly cleaner and no further antibiotics were prescribed. Fluorescence images enabled real-time monitoring of antibiotic treatment effectiveness and avoided time delays associated with microbiological (swab) confirmation.

### Fluorescence Detection of *Pseudomonas aeruginosa*



Standard Imaging Mode      Fluorescence Imaging Mode

32-year-old male suffered purpura fulminans following streptococcal septicaemia, affecting 50% of his total body surface area. Fluorescence images revealed small pockets of *P. aeruginosa* colonization (cyan, arrows), enabling swabs to be taken from these specific regions.

Swabs confirmed heavy growth of *Pseudomonas aeruginosa*.

## CONCLUSIONS

- Using the bacterial fluorescence imaging device is similar to using any smart, touchscreen technology.
- By detecting bacteria at the point of care, we may be able to prevent bacterial levels from reaching critical colonisation, infection, and sepsis. Thus, this research has significant implications for improving overall healing.
- Early intervention could reduce the likelihood of graft failure, while fluorescence guided swabs to determine precise bacterial species present will enable targeted antibiotic therapy, with the goal of preventing antibiotic resistance.
- In summary, bacterial fluorescence imaging provides guidance for clinicians in regards to:
  - Immediate information on bacterial presence or absence,
  - Identifying the type of bacteria to be treated (specific detection of *P. aeruginosa*),
  - Pinpointing the location of bacterial presence for more accurate swabbing,
  - Antimicrobial and antibiotic decision making and monitoring of treatment effectiveness.

## REFERENCES

1. Bowler PG et al, Wound microbiology and associated approaches to wound management. Clinical Microbiology, 2001.
2. DaCosta RS et al. Point-of-Care Auto-fluorescence Imaging for Real-Time Sampling and Treatment Guidance of Bioburden in Chronic Wounds: First-in-Human Results, PLoS ONE, 2015.
3. Wu YC et al. Handheld fluorescence imaging device detects subclinical wound infection in an asymptomatic patient with chronic diabetic foot ulcer: a case report. International Wound Journal, 2015.
4. Ottolino-Perry et al. Improved detection of wound bacteria using autofluorescence image-guided wound sampling in diabetic foot ulcers. International Wound Journal, 2017.
5. Rennie MY et al. Point-of-care fluorescence imaging positively predicts the presence of pathogenic bacteria in wounds at loads  $\geq 10^4$  CFU/g: a clinical study. J Wound Care (submitted).