

Handheld real-time bacterial fluorescence imaging guides wound cleaning and facilitates patient education in pilonidal sinus wound care patients



Rose Raizman, RN-EC, MSc, MNurs, PHCNP, CETN
Scarborough Rouge Health System, Toronto, Canada

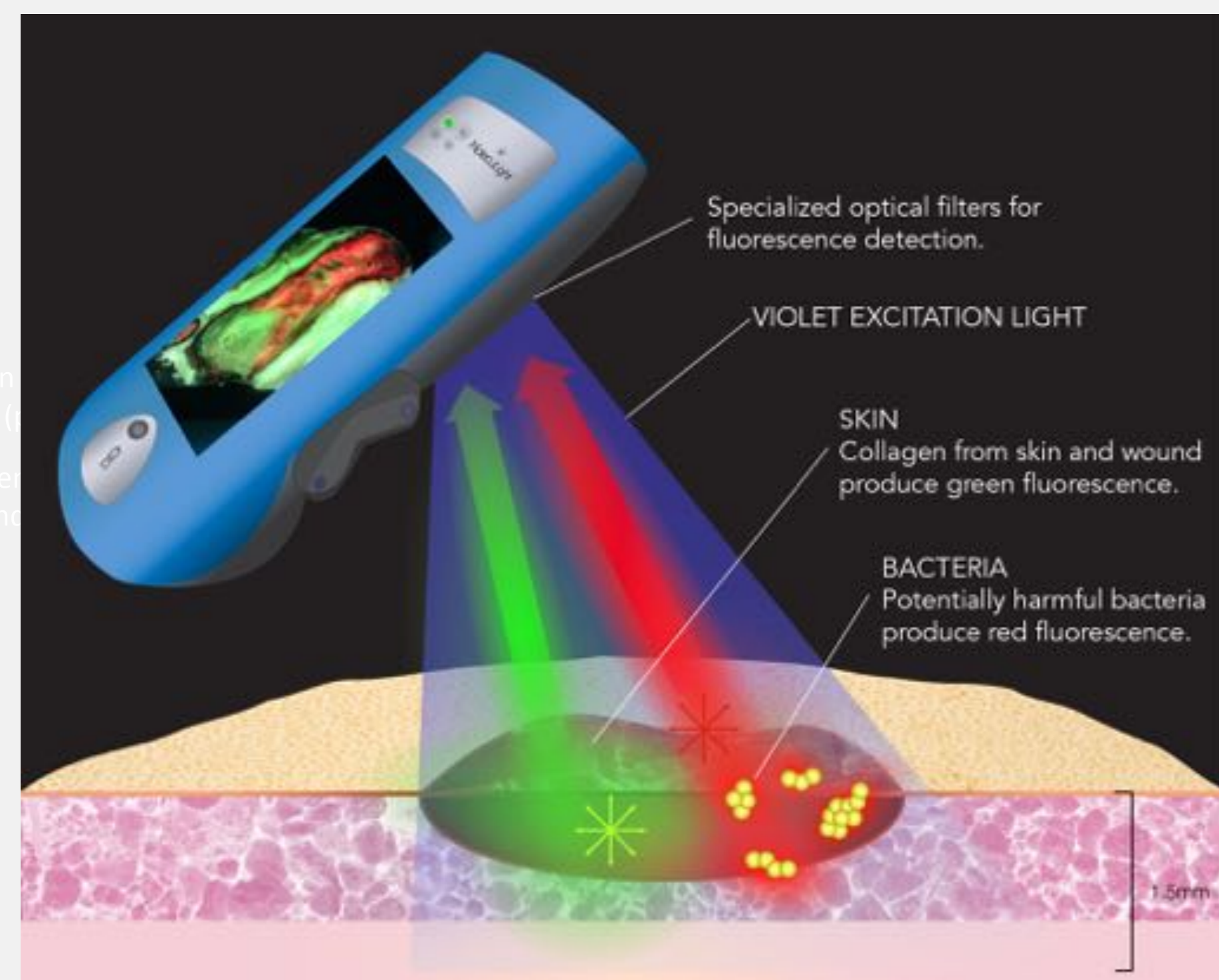
INTRODUCTION

- Wound care following surgical removal of a pilonidal sinus is challenging due to proximity to the anus and the warm, moist, dark environment where bacteria can thrive¹.
- Two of the most common challenges in post excision pilonidal sinus wound care are: (1) unrecognized superficial critical bacterial colonization and (2) inadequate personal skin cleansing (secondary contamination)¹, which can lead to infection and delay healing.
- Detecting bacterial presence based on clinical signs and symptoms is difficult as bacteria are invisible to the naked eye. To address this problem, **fluorescence imaging has recently been used to visualize bacteria, which fluoresce red in real-time at the bedside using a non-contact hand-held device^{2,3}.**
- We report the use of bacterial fluorescence imaging to: (1) detect and monitor the presence of bacteria in pilonidal sinus patients and (2) guide clinician and patient wound cleaning regimes.

METHODS

Bacterial Fluorescence Imaging

- When excited by 405 nm violet light, tissues fluoresce **green** while bacteria fluoresce **red**.
- This enables real-time, point-of-care detection and localization of bioburden ($\geq 10^4$ CFU/g) within and around wounds^{2,3}.

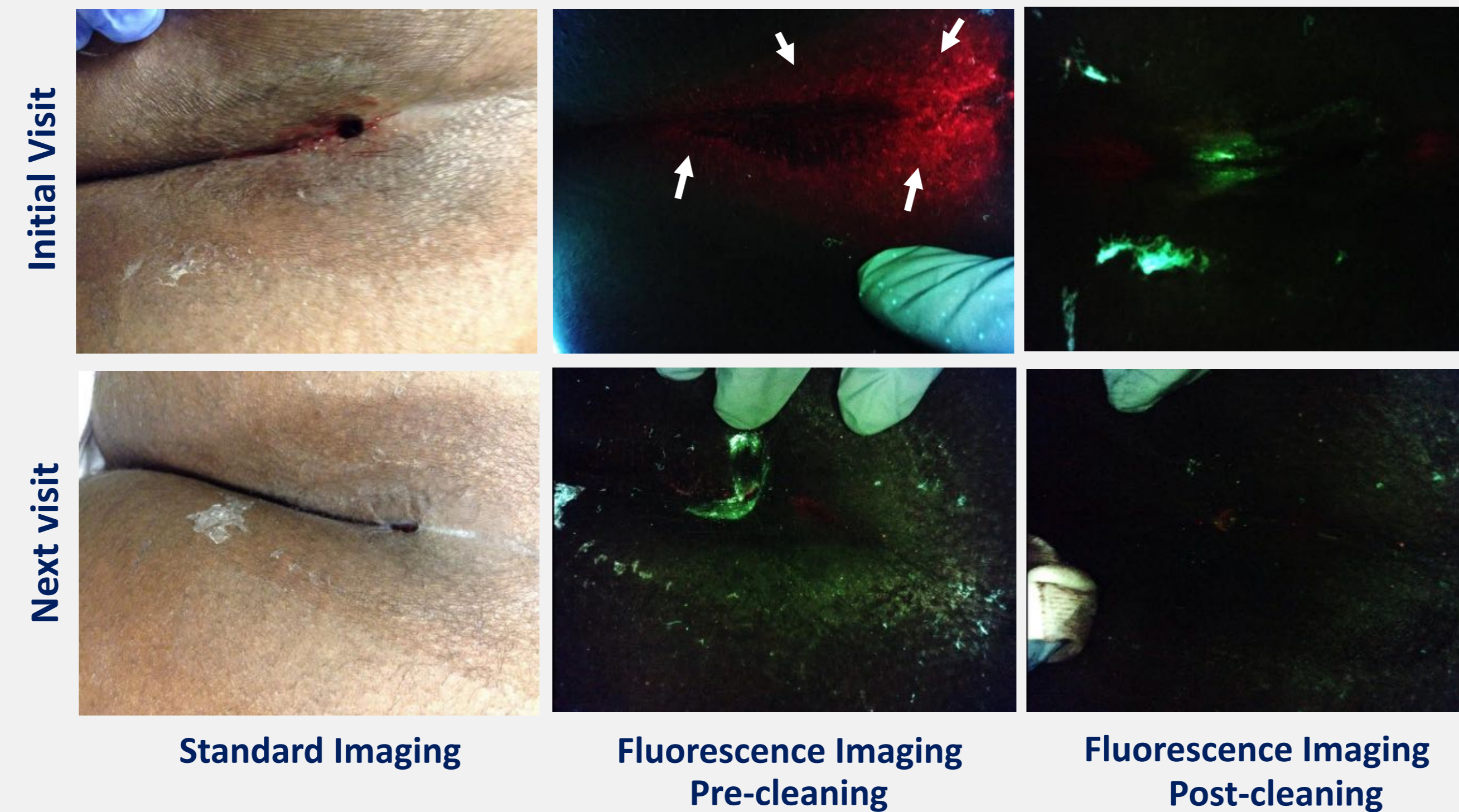


Pilonidal sinus patients (n=9) were imaged pre- and post wound cleaning during routine wound care to monitor the presence of bacteria, guide wound cleaning, and educate patients on home care cleaning practices.

Pilonidal sinus wounds that fluoresced red (7 of 9 patients) were considered positive for bacteria and received additional cleaning.

RESULTS

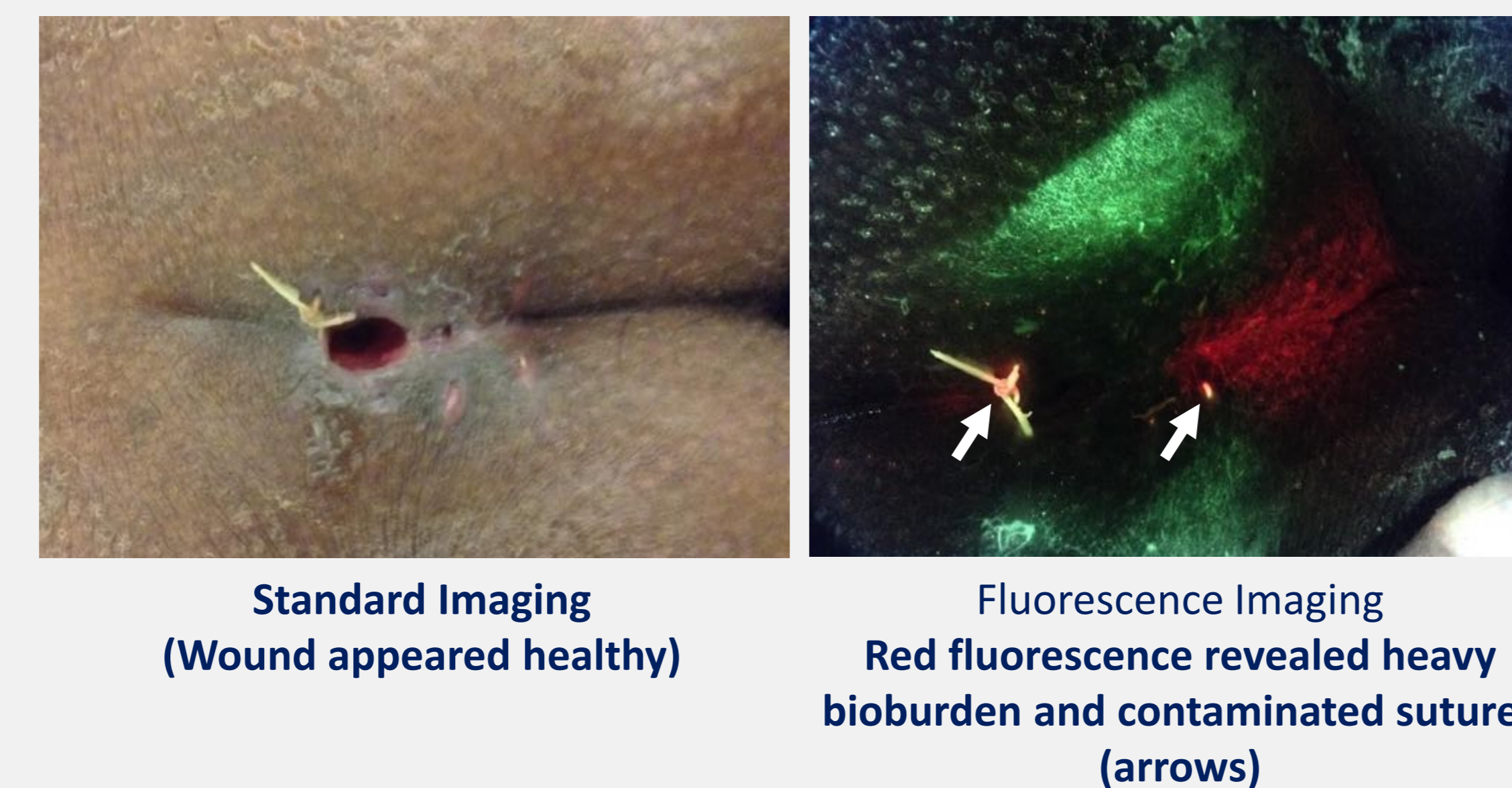
Images of Bacteria Improve Patient Understanding and Adherence to Wound Cleaning Regimes



Previously healed pilonidal sinus patient (15 year old female) presented with a re-opened surgical site. Red (bacterial) fluorescence was observed in the gluteal cleft. Images were used to educate the patient on bacterial presence and location and at-home cleaning practices that should be regularly performed.

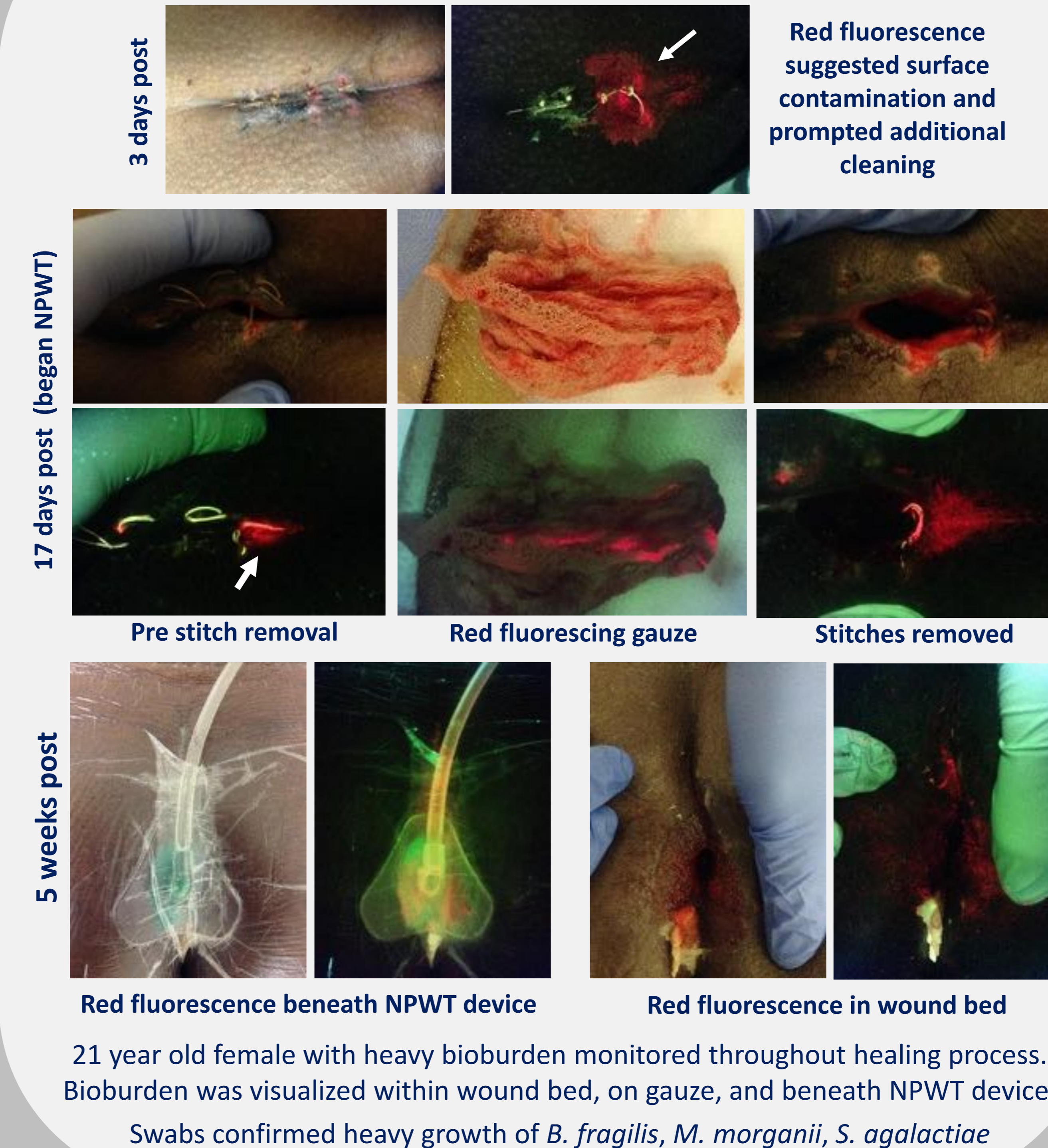
One week later, bacterial fluorescence was no longer present, suggesting adherence to at-home wound care regime.

Detection of Contaminated Sutures Prompts Early Removal

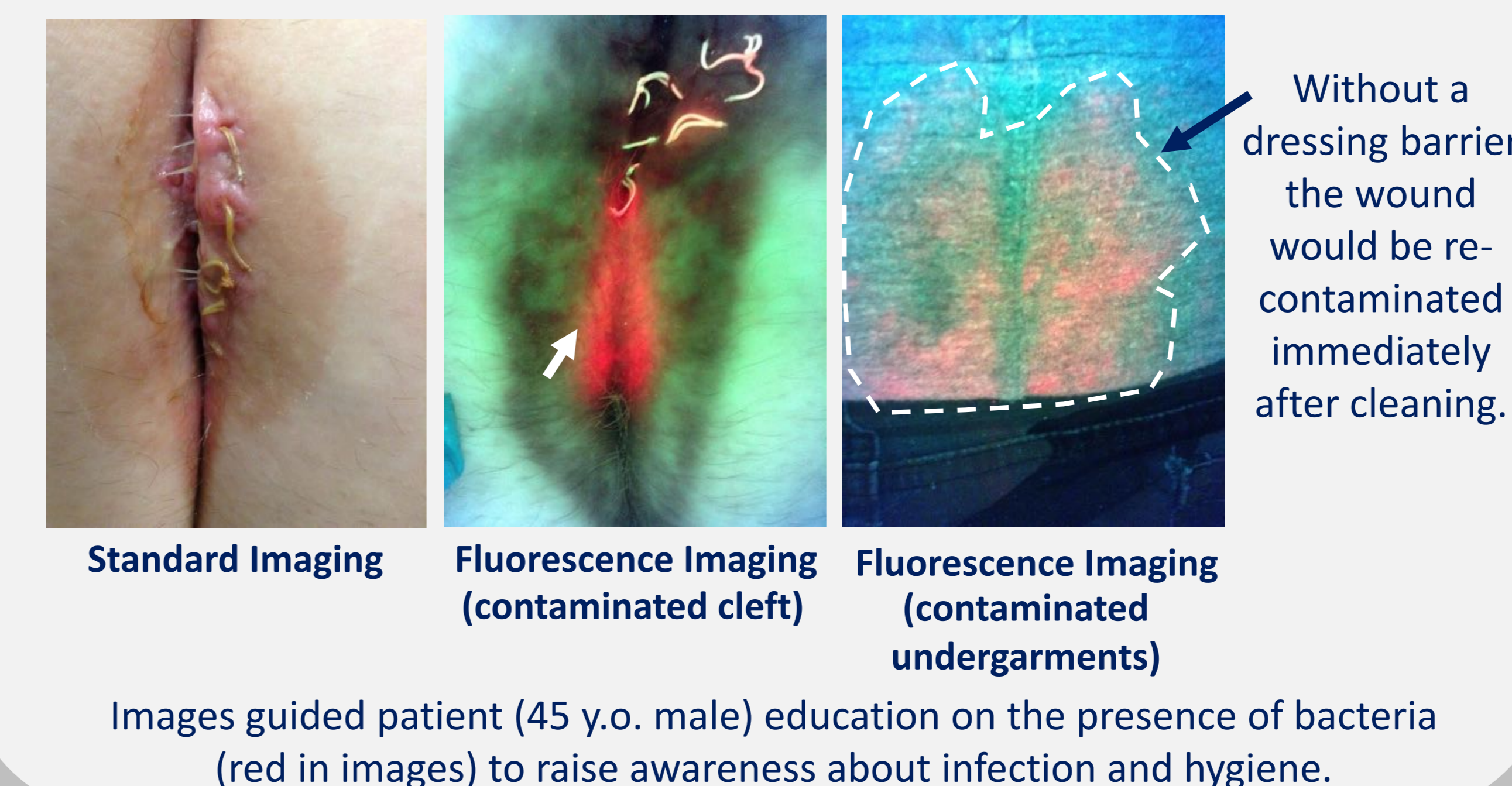


Previously healed pilonidal sinus patient (25 year old female) presented with a re-infected surgical site. Red (bacterial) fluorescence was observed throughout the gluteal cleft. **Fluorescence guided cleaning of the wound revealed contaminated sutures, prompting their early, immediate removal.** Images were used to educate the patient on bacterial presence and location and at-home cleaning practices that should be regularly performed.

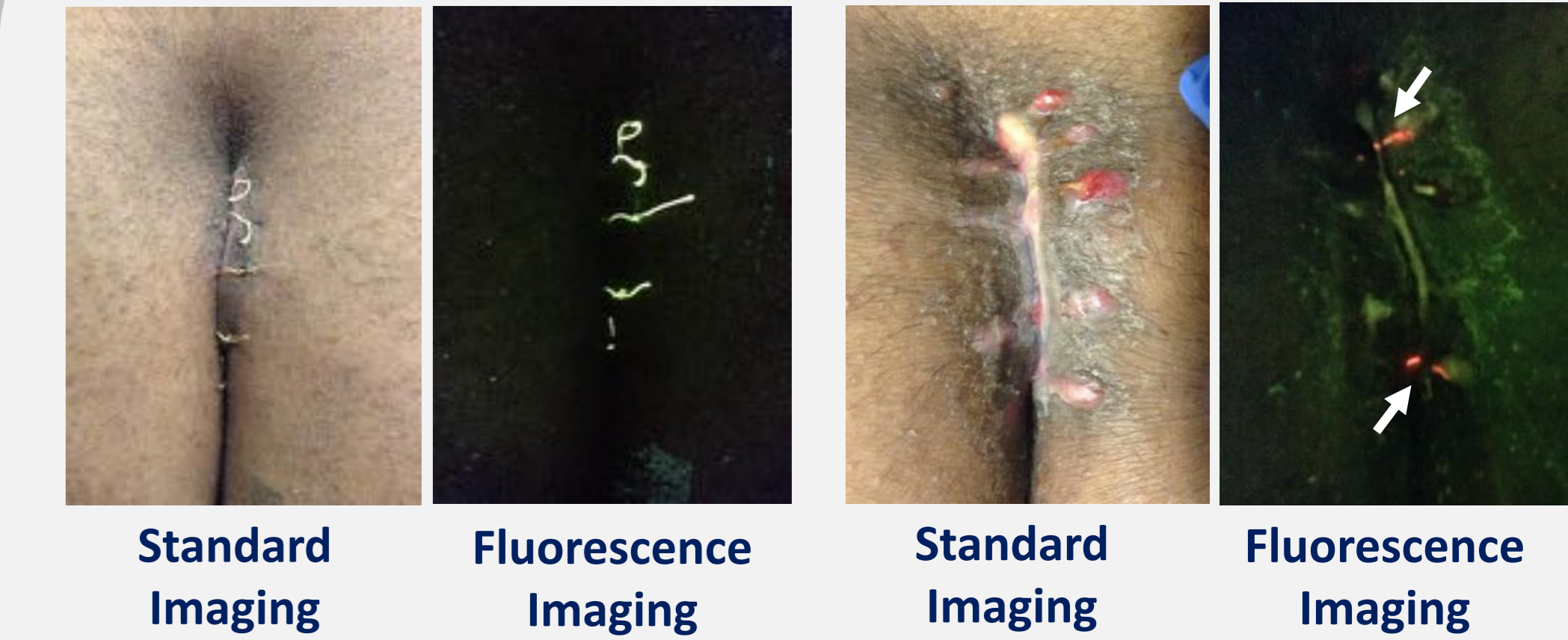
Bacterial Presence Monitored Throughout Post-Surgical Wound Healing



Bacterial Contaminated Wound & Undergarments



Bioburden Free Wound Light Surface Bioburden



Real-time visualization of wounds with no or light bioburden helped the clinician to determine (1) the effectiveness of treatment regime (including selected antimicrobial dressings) and (2) home care and patient adherence to wound cleaning protocols.

CONCLUSIONS

- Bacterial fluorescence images guided the extent and location of clinician cleaning and prompted an instance of early suture removal.
- Visualizing bacteria, which the patient otherwise could not have seen, provided enhanced awareness of their infection risk and facilitated patient education.
- Bright and simple colours (**green = tissue, red = bacteria**) on fluorescence images made it easy for patients to understand when and where bacteria was present. An improvement in patient adherence was observed.
- Results highlight the potential of this novel imaging device to guide clinician treatment in cases where bacterial contamination could impede wound healing and to improve patient understanding and adherence to home cleaning and hygiene protocols.

REFERENCES

- Harris CL, et al. Twelve Common Mistakes in Pilonidal Sinus Care. *Advances in Skin and Wound Care*. 2012 July 25(7): 324-332.
- DaCosta RS et al. Point-of-care autofluorescence imaging for real-time sampling and treatment guidance of bioburden in chronic wounds: first-in-human results. *PLoS One*. 2015 Mar 19;10(3)
- Rennie MY et al. Point-of-care fluorescence imaging positively predicts the presence of pathogenic bacteria in wounds at loads $\geq 10^4$ CFU/g: a clinical study. *J Wound Care* (submitted)

Acknowledgement: Financial support to attend this meeting was provided by MolecuLight, Inc. The bacterial fluorescence imaging device used in this study is manufactured and sold by MolecuLight, Inc.